

Positron Emission Tomography in Oncology

by Andrew G. Jones '01

Positron emission tomography (PET) sounds like an obscure physics phenomenon, but the images this clinical scan produces are some of the most accurate and elucidating in all of nuclear medicine and radiology. Unlike magnetic resonance imaging (MRI) or computerized axial tomography (CAT) scans that depict structure of tissue, PET displays various physiologic functions. This is done by using a special type of radioactive decay known as positron emission to label molecules that mimic physiologic substrates. Special software then assembles the data into "slices" which in turn may be rendered in three dimensions. This imaging technique is rapidly gaining favor among physicians due to its potential impact on patient management, including tailoring therapy to an individual's particular needs.

The basic concept behind PET is comprehensible enough, but the successful harnessing of the phenomenon for diagnostic purposes has required nearly 20 years of engineering to perfect. Positrons are particles emitted through the normal decay of protons of some radioactive atoms including ^{11}C , ^{15}O , and ^{18}F . Rapidly losing energy, the positron travels about a millimeter through the surrounding tissue before slamming into an electron. This annihilation event converts the matter of the two particles into pure energy in the form of two 511 keV photons traveling at 180 degrees to each other. These photons escape the body and strike a detector (usually in the form of a ring) made of crystals of bismuth germanate surrounding the patient. If two photons strike a pair of these detectors within a certain window of time (for example less than 15 nanoseconds), the scanner considers the photons to have originated from the same annihilation event. This "coincidence" allows a line of response to be drawn between the two locations on the ring, yielding a range of tissue in which the isotope could be located.

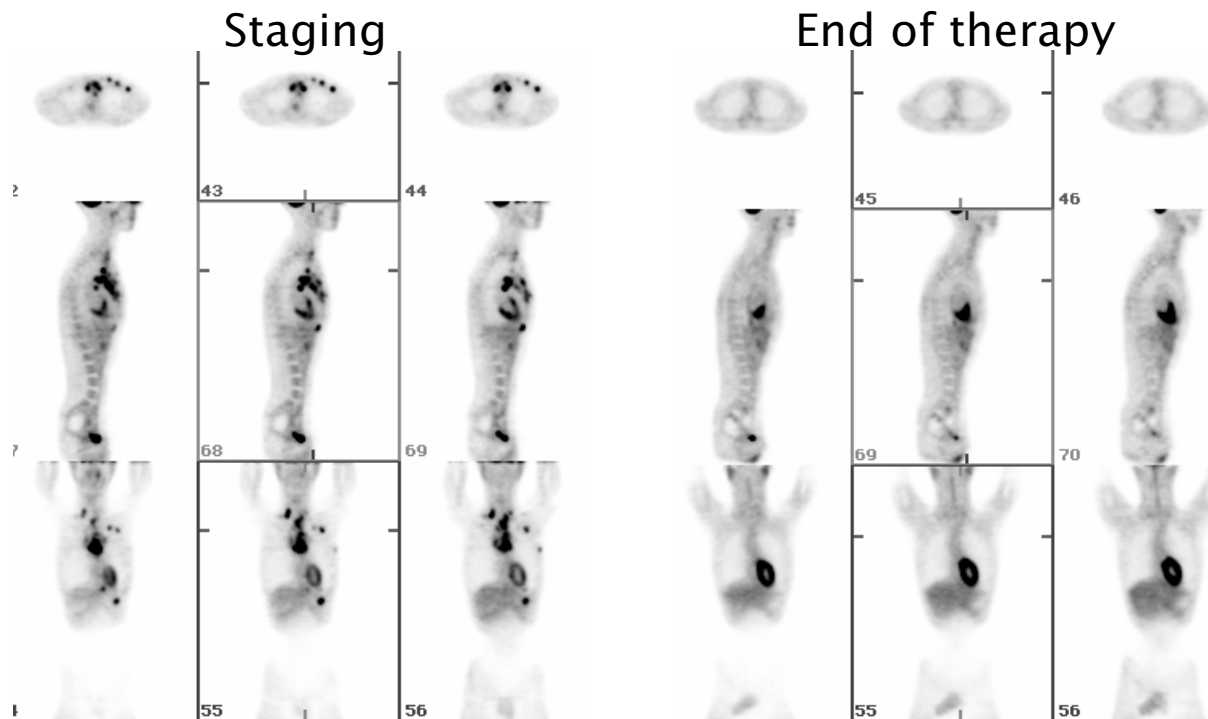
Hundreds of thousands of these lines allow computational analysis and temporal and spatial pinpointing of the isotope within the patient. Complex algorithms then use the data to render the imaging slices and generate a whole-body image.

Unstable positron-emitting isotopes do not exist naturally. They must be industrially synthesized employing a cyclotron unit that uses high-powered magnets to accelerate beams of protons, smashing them into stable isotopes. The radioactive isotopes are then attached to the compound that will ultimately be injected into the patient. Unfortunately, these complex machines are expensive (on the order of two million dollars) and require a team of specialized personnel to operate and maintain; thus there are few in existence.

The cost of cyclotron production, combined with the fact that the positron-emitting isotopes have short half-lives (2.1 minutes for ^{15}O up to 109 minutes for ^{18}F), means that the patient doses themselves are currently quite expensive (nearly \$600!). However, as PET facilities and cyclotrons become more numerous, the cost should go down, increasing both test availability and accessibility to patients.

Positron-emitting atoms are often attached to normal body chemicals with the intent to measure a specific physiologic process. The most common radioactive compound currently used in PET scans is a glucose analogue called ^{18}F -fluoro-2-D-deoxyglucose (FDG). Glucose, one of the body's primary energy sources, is transported into cells where it enters the glycolytic pathway to produce energy. Hexokinase, the first enzyme of the pathway, adds a phosphate to the sixth carbon of glucose; the compound is then morphed into fructose-6-phosphate by glucose-6-phosphate isomerase. FDG is also transported into cells, but is unable to continue in the pathway once phosphorylated by hexokinase. Thus it tends to accumulate

*Information
may not only allow
treatment to begin before
tumors have grown large,
but in some cases before
they have metastasized.*



Hodgkin's Lymphoma pre-treatment (staging) images were obtained using a dedicated PET scanner. Extensive disease is noted in supraclavicular, mediastinal, axillary, diaphragmatic, paratracheal and pectoral nodes.

Hodgkin's Lymphoma post-treatment images were obtained using a dedicated PET scanner. Resolution of sites previously mentioned suggests disappearance of disease. Images are courtesy of Annick D. Van den Abbeele, M.D. Director, Nuclear Medicine, Dana-Farber Cancer Institute, Boston, Massachusetts.

in tissue and becomes what is known among PET scientists as “metabolically trapped” in tissues that are particularly glucose-avid.

Cancer cells tend to accumulate a great deal of FDG, both because these cells express higher concentrations of the transporters responsible for ferrying glucose into cells from the blood and because the equilibrium of the conversion of glucose to glucose-6-phosphate is shifted to favor the product, further driving the metabolic trapping. It is therefore not surprising that one of the most significant contributions FDG-PET has made in the last few years is in the field of oncology. The PET images reveal to the reading physicians the locations of tumors lurking in the body. FDG scans have proven extremely effective in diagnosing and determining the stage of certain cancers as well as monitoring patient response to therapy and aiding in long-term management.

This past summer I had the privilege of observing these astounding images with Dr. Annick D. Van den Abbeele, Director of the Nuclear Medicine Department of the Dana-Farber Cancer Institute in Boston. The impact of PET imaging on patient diagnosis and possibly prognosis quickly became apparent to me as I viewed the images. I was astonished at the clarity of the images Dr. Van den Abbeele managed to achieve with the dedicated PET scanner (please see figure

for representative before and after treatment images of Hodgkin's lymphoma patient). PET clearly reveals the location of diseased areas before anatomic changes (palpable lumps or visible lesions) become apparent. While CAT and MRI provide exquisite anatomic information, they rely exclusively on changes in morphology of tissue to reflect the underlying physiology. Thus, temporally speaking, they cannot determine as accurately the state of disease.

This capacity of PET has tremendous implications for patient management with regards to surgery, chemotherapy and radiation therapy. The information may not only allow treatment to begin before tumors have grown large, but in some cases before they have metastasized. Furthermore, PET has the potential to reveal tumor death by therapy earlier than anatomic changes reflect. This temporal advantage may allow patients to avoid further treatment that can weaken their already besieged immune systems. In addition, the resolution capability of PET may permit more precise localization of a tumor, allowing physicians to deliver a stronger dose of anti-tumor drugs or radiation to the lesion while reducing the toxicity to the surrounding normal tissue. Finally, the overall cost of the scan (around \$2500!), while expensive in itself, may prevent unnecessary and even more costly procedures such as surgery. One time I listened as

Dr. Van den Abbeele examined the scan of a patient with a history of colorectal cancer scheduled for partial hepatic surgery. "That single hepatic lesion would be resectable if it were the only lesion, but the PET shows the disease has spread beyond the liver to the lungs. Interesting that the CT didn't reveal anything. He won't be considered a surgical candidate now. They may have to change their therapeutic approach." Despite the sudden change in prognosis I had just heard, I realized PET had saved the patient from the additional trauma and risk of surgery, something many patients cannot handle in their fragile state of health.

Unfortunately, as of yet, PET facilities are not widespread. Hopefully, as more physicians such as Dr. Van den Abbeele illustrate the immense clinical benefits PET has to offer, the greater medical community will more vehemently support this emerging technology.

For further information on the web, the author suggests the following sites:

-<http://www.crump.ucla.edu/lpp/shocked/lpp-shocked.html>

-http://nucmed.rad.washington.edu/web/teaching/physics_intro/index.html ❖

REFERENCES

Sorenson, J.A., Phelps, M.E. (1987). *Physics in Nuclear Medicine*. Second Edition. New York, Grune and Stratton.

Daube-Witherspoon, M.E., Herscovitch, P. (1996). Positron Emission Tomography. In Harbert, J.C., Eckelman, W.C., Neumann, R.D., *Nuclear Medicine. Diagnosis and Therapy* (pp 121-143). New York, New York: Thieme Medical Publishers.

Badawi, R.D. Private communication. July 2000.

Phelps, M.E., Hoffman, E.J., Selin, C., Huang, S.C., Robinson, G., MacDonald, N., Schelbert, H., Kuhl, D.E. (1978). Investigation of [18F]2-fluoro-2-deoxyglucose for the measure of myocardial glucose metabolism. *Journal of Nuclear Medicine*, 19, 1311 -1319.

Di Chiro, G., DeLaPaz, R.L., Brooks, R.A., Sokoloff, L., Kornblith, P.L., Smith, B.H., Patronas, N.J., Kufta, C.V., Kessler, R.M., Johnston, G.S., Manning, R.G., Wolf, A.P. (1982). Glucose utilization of cerebral gliomas measured by 18F fluorodeoxyglucose and positron emission tomography. *Neurology*, 32, 1323-1329.

Delbeke D. Oncological applications of FDG PET imaging. (1999). *Journal of Nuclear Medicine*, 40(10),1706-15.

Van den Abbeele, A.D. Private communication. July, 2000.

ABOUT THE AUTHOR:

Andrew Jones '01 hails from Newton, MA. He is a biology major and psychology minor. His interests include neurobiology and physiology. Andrew is currently considering medical school after graduation.